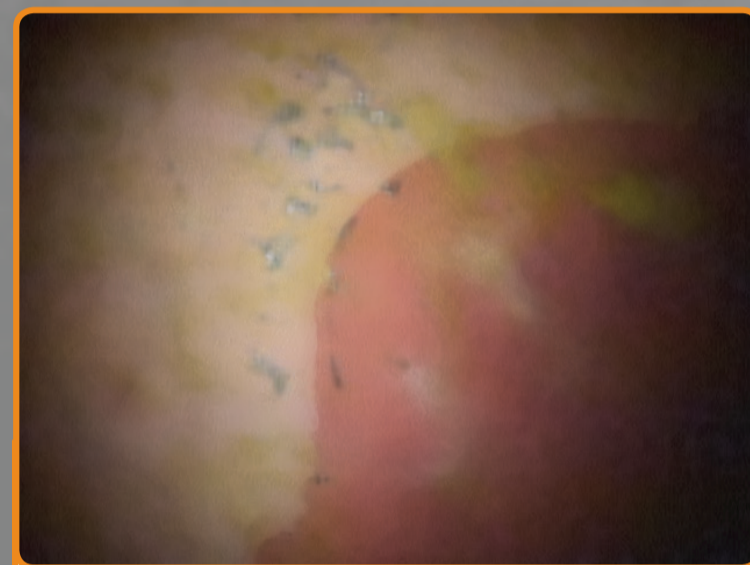


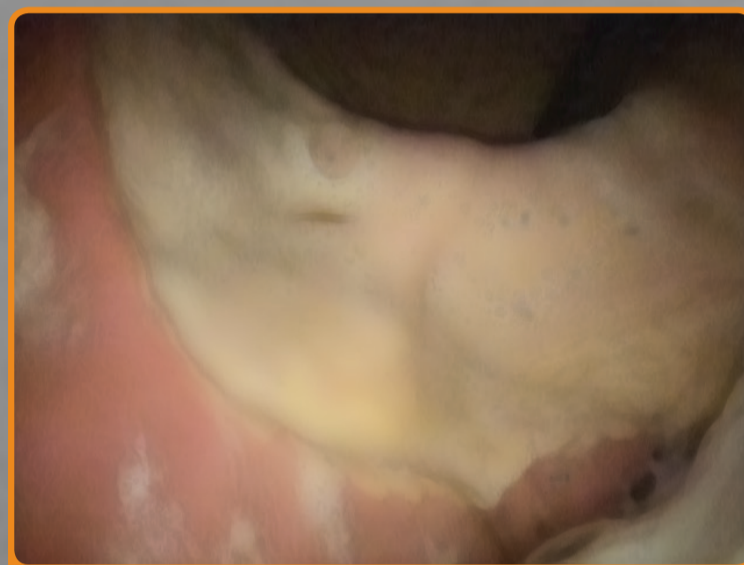# Equine Gastroscopy Guide



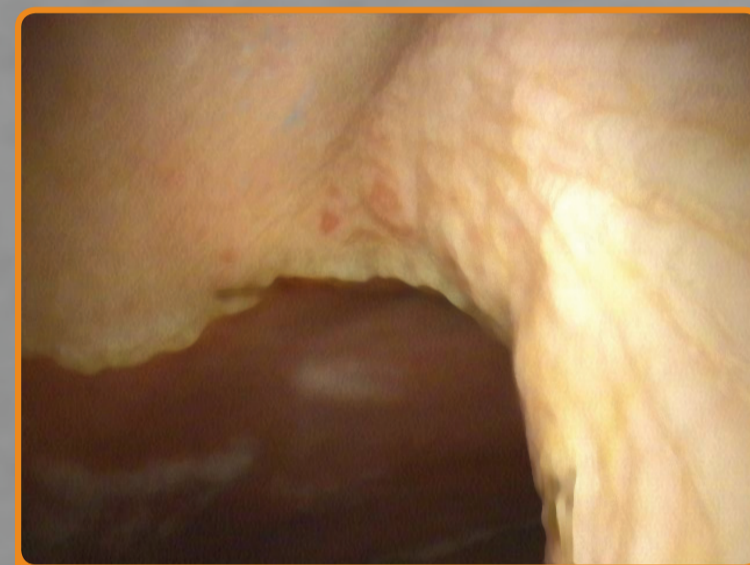## Squamous Ulceration Grading



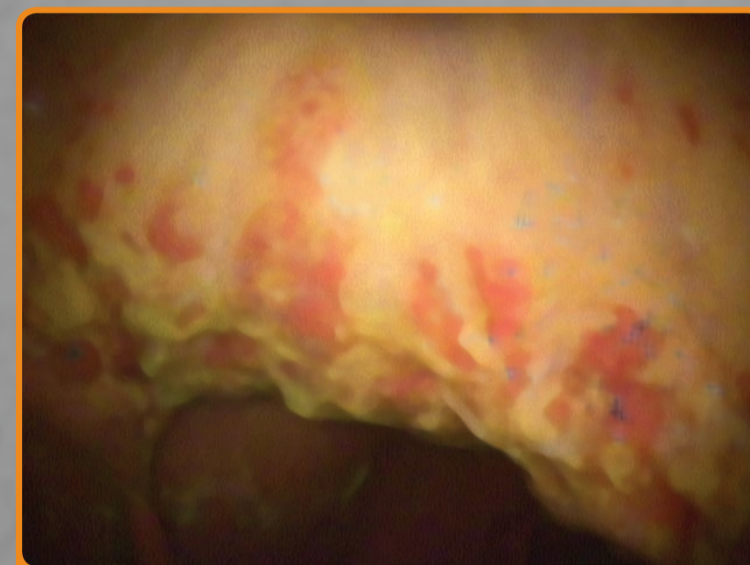
**Grade 0**  
The stomach lining is intact and there is no appearance of reddening or thickening



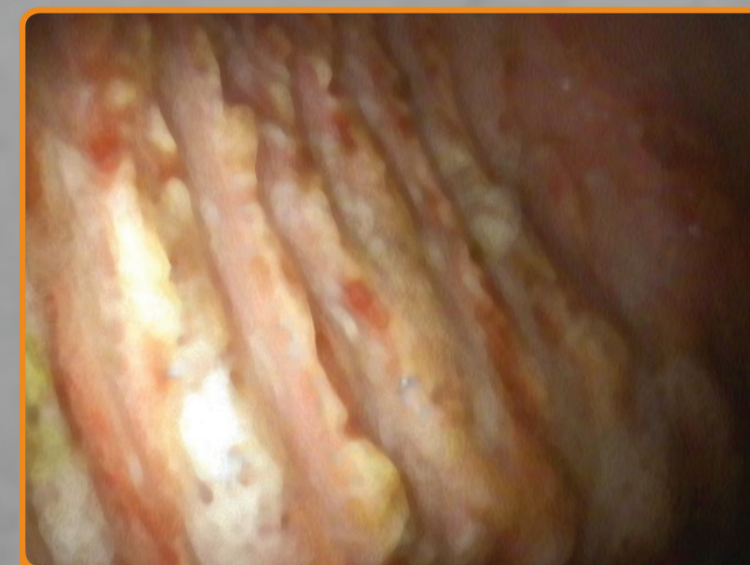**Grade 1**  
The mucosal is intact, but there are areas of reddening or thickening



**Grade 2**  
Small, single or multifocal lesions

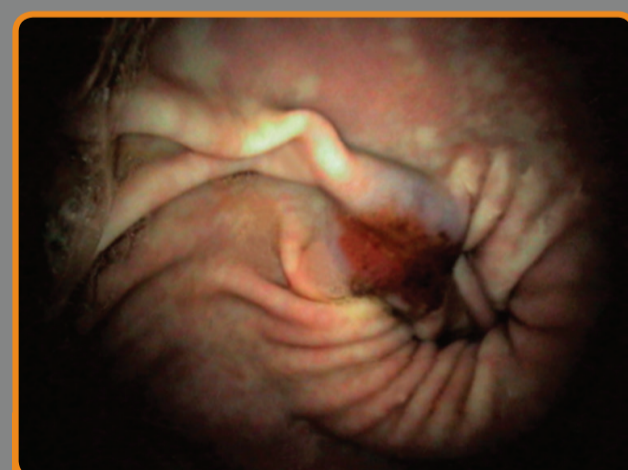


**Grade 3**  
Large, single or multifocal lesions or extensive superficial lesions

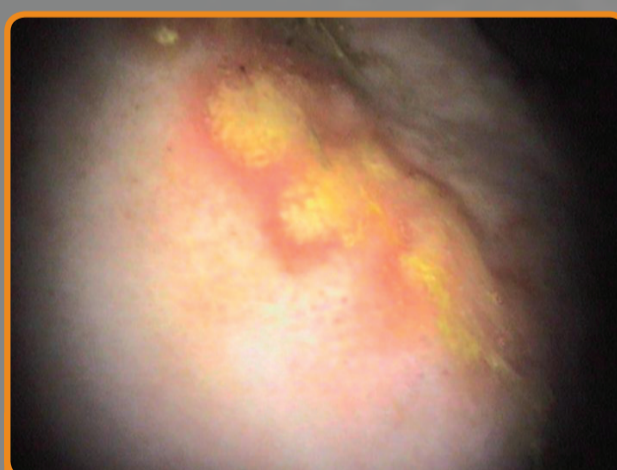

**Grade 4**  
Extensive lesions with areas of apparent deep ulceration

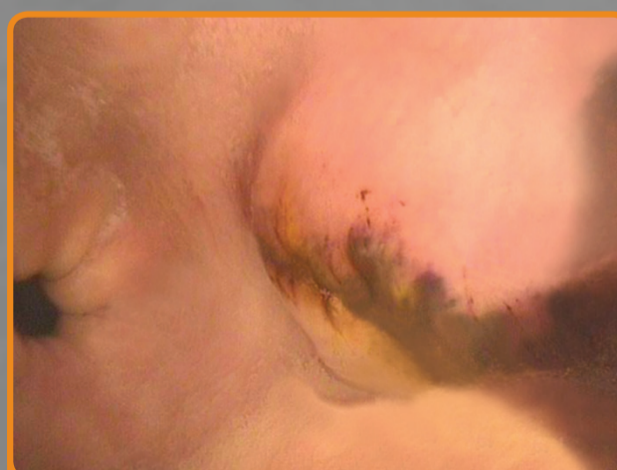## Glandular Descriptive Identification



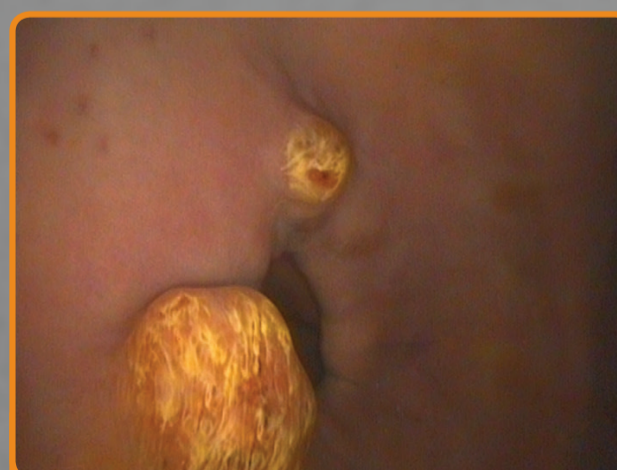**Flat and Haemorrhagic**  
Flat ulcer with bloody appearance



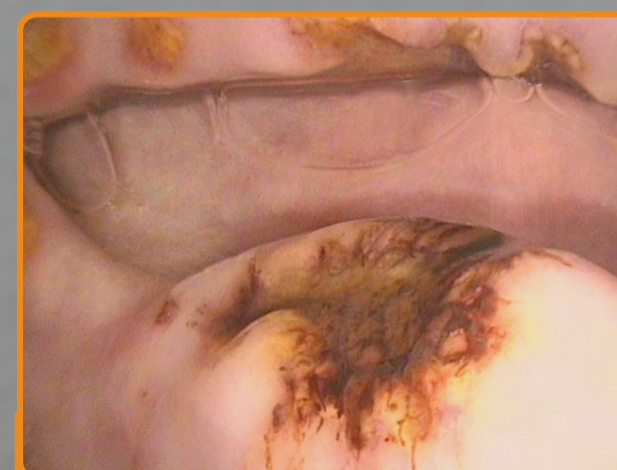
**Flat and Fibrinous**  
Flat ulcer with fibrous and discharging appearance



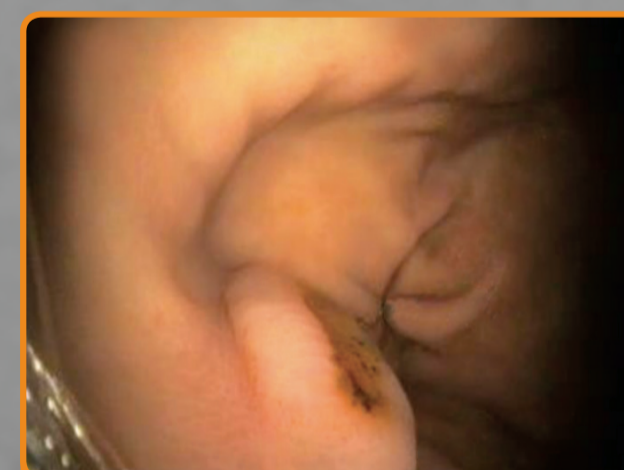**Raised and Haemorrhagic**  
Raised ulcer with bloody appearance



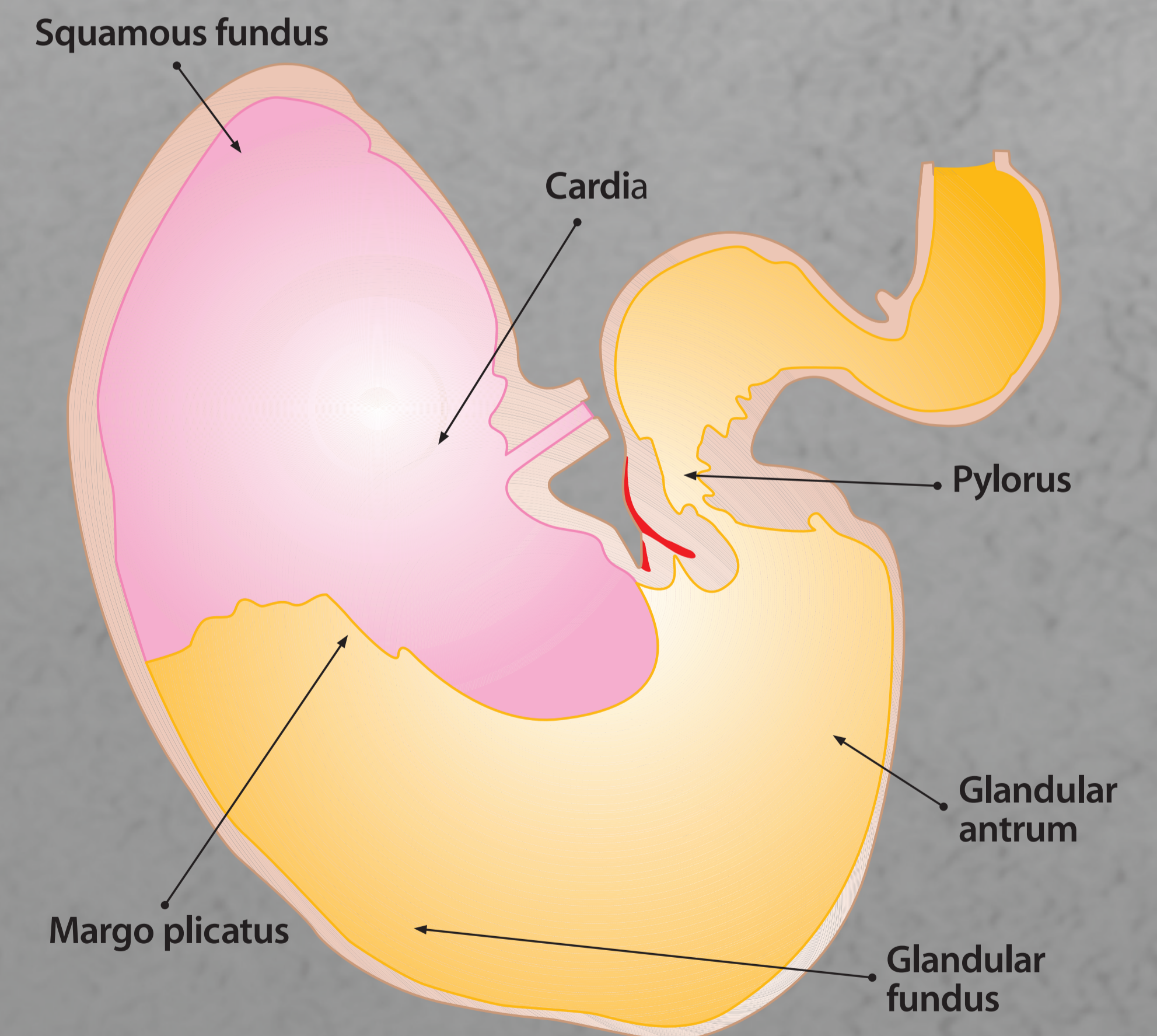
**Raised and Fibrinosuppurative**  
Raised ulcer with fibrous and discharging appearance



**Depressed +/- blood clot**  
Sunken ulcer with or without bloody appearance



**Depressed and Fibrinosuppurative**  
Sunken ulcer with fibrous and discharging appearance



Images kindly supplied by  
• David Rendle, Rainbow Equine Hospital  
• Nanna Luthersson, Equine Veterinary Specialist from Denmark